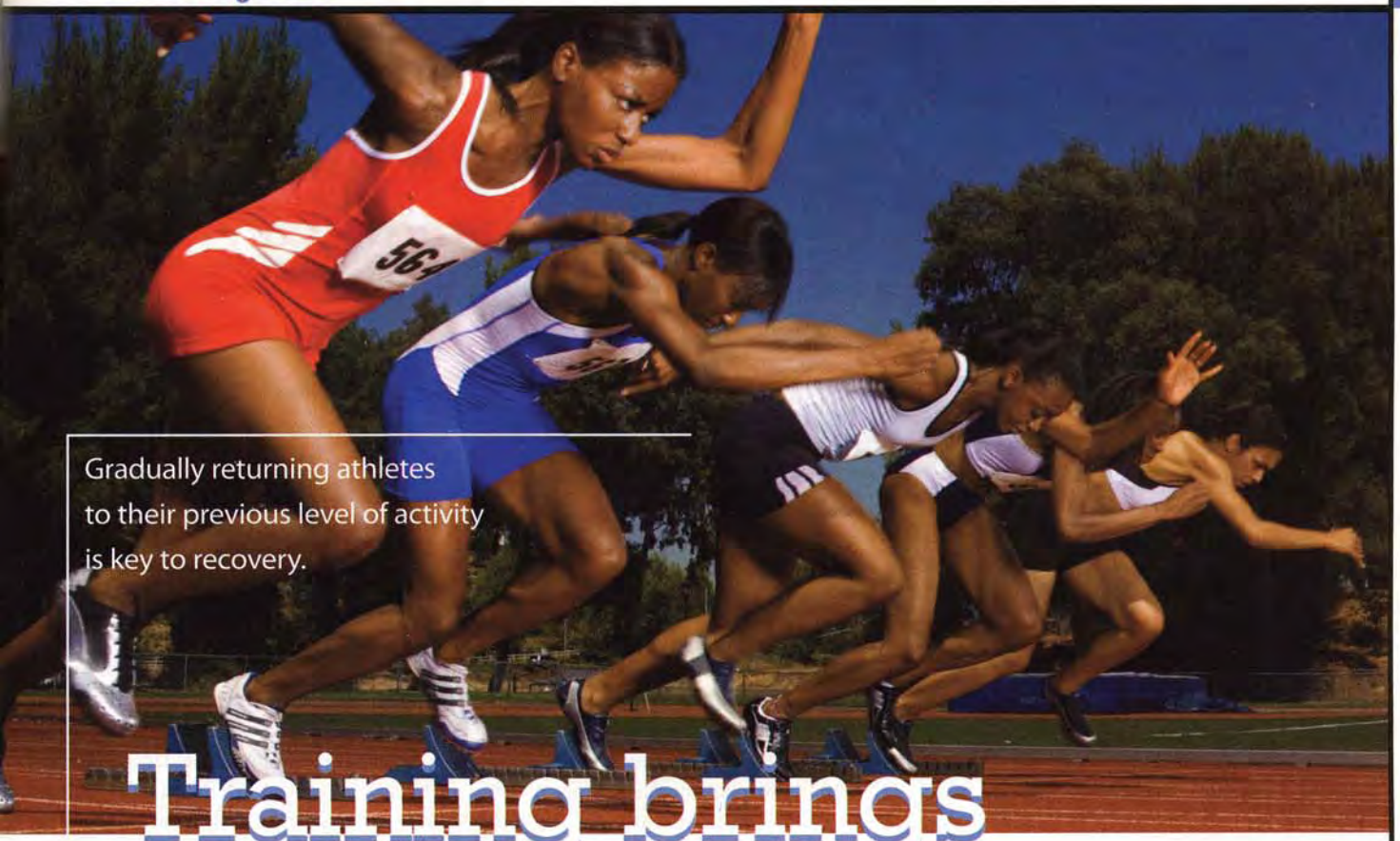

Gradually returning athletes to their previous level of activity is key to recovery.

Training brings athletes back after shin pain

Shin splints are one of the most common lower extremity injuries to beset athletes, especially those involved in sports like track and field, where bursts of running or jumping are the norm. The good news is that once a diagnosis and treatment plan are in place, most cases can be treated effectively with conservative care.

by Joshua Dubin, DC, Rachel Appel Dubin, DPT, and Gregory Doerr, DC

Returning the musculoskeletal support structures of the lower extremity to preinjury strength can take approximately 12 weeks for bones, 40 to 50 weeks for ligaments, six weeks to six months for muscles, and 40 to 50 weeks for tendons.

Goals of therapy are multifold. Reducing pain and promoting healing top the list. Of equal importance is the need to incorporate a modified training routine to maintain fitness, to correct or minimize potential risk factors, to gradually reintroduce pain-free sport-specific activity, and to allow the athlete to achieve realistic training goals.

As we discussed in the first article of this series ("Shin pain diagnosis requires multipronged clinical approach," May, page 45), shin splints result when excessive eccentric loads are placed on the lower leg musculature. Returning the musculoskeletal support structures of the lower extremity to preinjury strength is of paramount importance. This process can take approximately 12 weeks for bones, 40 to 50 weeks for ligaments, six weeks to six months for muscles, and 40 to 50 weeks for tendons.[1]

Several treatment modalities may aid in reducing pain and inflammation and in speeding up the body's normal healing response. Depending on the severity of the injury, however, time may be the essential limiting factor to recovery.

Inflammation can be reduced by taking nonsteroidal anti-inflammatory medications, per prescription. Also, applying a cold pack to the shin for 20 minutes on, one hour off, repeated throughout the day is also recommended. Another useful modality to decrease inflammation is iontophoresis with dexamethasone.[2-4]

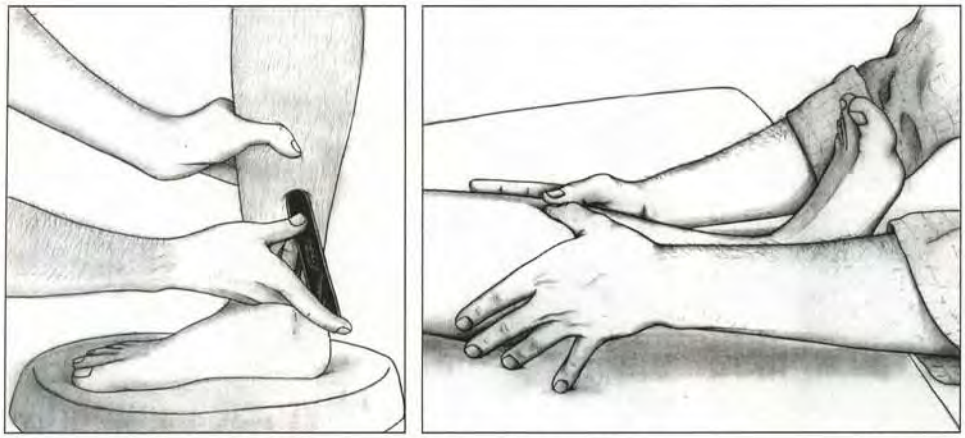

The Graston Technique (left) and the Active Release Technique (right) are deep tissue procedures that stimulate fibroblast proliferation. In the Graston technique, a special stainless steel instrument helps to break up scar tissue. (Illustrations by Audrey Mahoney)

Deep tissue procedures, such as the Graston Technique, a manual therapy that uses specially designed devices and the Active Release Technique, a patented manual therapy technique can break up scar tissue and restore soft tissue motion. Considerable clinical evidence supports the effectiveness of using these procedures in the treatment of both strain and sprain injuries.[10-13] Myofascial techniques have been shown to stimulate fibroblast proliferation, which leads to collagen synthesis. This may promote healing by replacing degenerated tissue with stronger and more functional tissue.[14,15]

Phototherapy, in the form of low-level laser therapy or the use of infrared light, can decrease inflammation, increase the speed of tissue healing, and decrease pain.[8,16]

Ultrasound and electrical muscle stimulation combination therapy can be used to restore normal muscle tone, aid in the healing process, and reduce pain.[2,3,5-8]

Manual adjustments to the ankle and foot can free up joint motion of the talocrural, subtalar, and midtarsal joint articulations.[7,9]

During the initial treatment phase for more severe grade two, three, and four injuries, cardiovascular fitness can be maintained with modified training. A runner, for example, should be instructed to cycle or swim at a pain-free level.[2,3,17]

©S. Carmona/CORBIS

Carolina Kluft of Sweden and Janice Josephs of South Africa ran in the footrace portion of the heptathlon at the 2004 Olympic Games in Athens. Kluft went on to win the gold for the overall event.

Sport-specific training

Although no studies detail exact recommendations for when to reintroduce sport-specific training, a few guidelines do exist.

If there are no time-specific training goals, cease sport-specific activity for two weeks initially and maintain cardiovascular fitness with modified training. After two weeks, pain-free running can be reintroduced on a soft track or treadmill, at approximately 50% of the preinjury training intensity and duration.

Increase the duration by 10% each week and keep the intensity at the same levels. Hopefully the athlete can reach his or her preinjury level in five to six weeks. Pain is a sign to cease running. It may be necessary to modify training for a brief period and to resume pain-free running at a lower intensity and for a shorter duration. Intensity of the training runs should be increased only once preinjury duration is achieved.[3,18]

My treatment protocols for returning an athlete to sport-specific training vary. Usually the initial training run will be two to four miles on a treadmill at a very slow pace speed (10-minute mile). After the athlete completes two or three of these runs without pain, I then create a program to achieve the athlete's time-specific goals.

Shoes and treatment tools

Practitioners may also recommend specific shoes and other treatment enhancements to help patients reduce the load placed on the musculoskeletal support structure of the lower leg by intrinsic risk factors.

Those with a pes cavus foot structure may benefit from a cushioned sneaker. The sneaker liner can be removed and replaced with a cushioned insole. Those with a rearfoot varus, pes planus valgus, and forefoot varus structure may benefit from a motion-control running shoe.[19]

A semirigid orthosis with a medial arch support no higher than 5/8-inch can help limit excess or prolonged pronation.[2,20-27]

Taping of the foot has been shown to be effective in limiting pronation.[7,28,29]

Use of a shin sleeve or strapping can add support to the leg muscles.

A dietitian can calculate caloric burn rate from daily exercise and then develop an appropriate daily meal plan for healthy weight loss or maintenance and to ensure proper nutritional requirements.[3]

Women who are experiencing amenorrhea may want to visit their primary doctor or a gynecologist to rule out low estrogen levels. Bone measurement testing may also be recommended.[3,30]

A 1/4- or 3/4-inch heel lift can be used temporarily to limit compensatory pronation caused by ankle equinus. As range of motion of the talocrural joint in dorsiflexion improves with therapy, the heel lifts can eventually be removed.[2,22,25]

Flexibility training may also help reduce compensatory pronation due to ankle equinus. The posterior calf musculature can be stretched with the knee extended and later bent, on either a slant board or a flat-floor surface, or with a prostretch device.[2,23,31-33]

Recalcitrant cases

The practitioner needs to continually reevaluate the athlete during the course of therapy. If the athlete has time-specific goals and is not responding to conservative care, or if symptoms reappear when sport-specific training is reinitiated, a bone scan or MRI may be needed to differentiate between the possibility of lower leg pain from a bone stress reaction, medial tibial stress syndrome (MTSS) anterior tibial stress syndrome (ATSS), or other pathology. Early recognition of a bone stress reaction may be treated with a short period of modified rest. The treatment recommendation of several months of protective weight-bearing for a more severe stress fracture was based on a poor treatment algorithm.[17,34]

Treatment of slow-healing stress fractures may require immobilization with casting or a walking boot for approximately three to eight weeks.[5,35] Pain-free modified training can maintain the athlete's cardiovascular fitness—and sanity—during this period. Once union of the stress fracture is evident on repeat imaging studies and pain is not present with ambulation, sport-specific training can gradually be reintroduced.

If, after four to six months of immobilization and rest, the stress fracture is shown on repeat imaging studies not to have healed, surgical intervention may be necessary. Procedures to enhance union of bone may include intramedullary nailing, cortical drilling, or an open procedure with excision and bone grafting.[2,35-37]

In recalcitrant cases of MTSS, surgical treatment options may include fasciotomy of the posteromedial superficial and the deep fascia of the tibia.[2] Posteromedial fasciotomy may aid in alleviating the pull of the soleus and deep posterior calf musculature of the leg on their insertions on the tibia and may decrease pain due to denervation of the periosteum.[3,18]

Postfasciotomy studies have indicated good results in reducing

shin pain. Many athletes, however, are not able to return to full sport-specific training levels.[23,37] Fasciotomy of the involved lower leg compartment may be an option to reduce shin pain due to exercise-induced compartment syndrome that has been resistant to conservative care over a period of six to 12 weeks.[23,35]

Training gets fine tuned

More specific aspects of training can also be introduced as the athlete exhibits progress in training.

Uphill training should be added gradually and conducted at a slower pace. Running uphill results in greater energy expenditure because of increased arm and shoulder action, and hip flexor and knee lift. An increased eccentric strain on the posterior calf musculature also occurs when running uphill. Downhill running should be limited because of an increased risk of injury and limited training benefits.[40,42]

Running shoes should be changed every 300 to 500 miles (or approximately every three to four months). A sneaker loses approximately 50% of its ability to absorb ground reaction forces after that.[2,3,18,31,43]

Modified training can be conducted on nonrunning days or while recovering from an injury. Exercise options include swimming, bicycling, and use of the elliptical machine. Older athletes (those 40 and over) can tweak their training program by reducing the time spent running on pavement and substituting modified training instead.[2,14,35,44,45]

Implementation of an eccentric strength training program for the lower leg musculature may aid in the treatment and prevention of injury.[46] Standing and seated calf raises strengthen the gastrocnemius, the soleus, and the intrinsic musculature of the foot. Using a dorsiflexion-assisted resistive device, resistive tubing, or a cable machine can strengthen the tibialis anterior and the extensor muscles of the leg that decelerate foot slap.[2,23,31,35,47-49]

The strength training program should address the whole lower kinetic chain.[35] Squats eccentrically strengthen the quadriceps, hamstrings, and gluteal muscles. Romanian deadlifts eccentrically strengthen the hamstrings and gluteal muscles.[50] Abduction, adduction, and hip extension exercises can be conducted with a cable machine or tubing. Based on my training experience, this lower extremity routine should be conducted once per week. If the long run is conducted on a Saturday or Sunday, I recommend that the strengthening routine take place on a Tuesday, Wednesday, or Thursday.

Static and ballistic stretching both have been shown to increase flexibility of the lower extremity.[51,52] After long-duration training runs or bike rides, a postworkout static stretching routine can help decrease cramping and muscle soreness.

A preseason conditioning program that includes plyometrics can jump-start the bone remodeling process and prepare the lower extremity support structures for the elevated eccentric workloads associated with running.[20,30,46,53-56]

Every athlete has individual training needs. The generic marathon training schedules, although helpful, may need to be modified for each individual in order to maximize gains and minimize risk of injury. An experienced training coach can help the athlete achieve his or her goal by customizing a training program and reassessing progress based on training logs and patient exertion levels.

READY TO GO THE DISTANCE

When patients fully recover from shin splints and can resume long-distance training, they are advised to follow these recommendations concerning frequency, intensity, and duration of runs.[2,38-40]

Aerobic conditioning. **Training at 70% to 80% of maximum heart rate (max HR = 220 minus age) is recommended for gradual adaptation to workloads with both cardiovascular conditioning and connective tissue adaptation.**

Initially, long-distance runners should establish a training base of four miles at this low-intensity training level. A progressive training schedule may later include a frequency of four runs per week; three shorter runs (approximately four to six miles) during the week; and a long training run on the weekend.[41]

Miles run per week should not be increased by more than 10% at a time. Based on marathon training logs and personal experience, the duration of the long run is usually increased by an increment of two miles per week or every other week, and the intensity should continue at the aerobic conditioning pace. After an appropriate base is established, the short-duration runs can be conducted at an increased intensity level.

Anaerobic conditioning. **This training intensity, conducted at 80% to 90% of maximum heart rate, is below lactate threshold, the point after which blood lactate levels rise rapidly and lead to increased ventilation (e.g., talking to a training buddy becomes difficult) and eventual muscle fatigue. Anaerobic conditioning should include a five-minute warm-up, followed by a 15- to 20-minute duration at the anaerobic conditioning training level, then a one-mile recovery run at the aerobic conditioning pace, followed by another 15-**

© Charles O'Rear/CORBIS

to 20-minute run at the 80% to 90% training level.

Anaerobic threshold training makes running at a submaximal lactate threshold training pace more manageable over a prolonged duration. Ideally, the marathon pace should be conducted slightly below the lactate threshold level. Toward the end of the race, at "the last kick," the pace can be increased.

Aerobic capacity training (intervals). **This training level, at 90% to 95% of maximum heart rate, is a vigorous challenge to the athlete's aerobic and anaerobic capabilities and stimulates both slow-twitch and fast-twitch muscle fibers. This pace should be maintained for only six to nine minutes, followed by a four to five-minute recovery run at a slow pace. These training runs elevate the lactate threshold and condition the body to deal more efficiently with oxygen debt and muscle fatigue.**

—JD, RAD, GD

Conclusion

Most cases of shin splints can be treated successfully with conservative care. A treatment plan may include modalities to reduce pain and inflammation, modified training to maintain cardiovascular fitness, training gear modifications to limit increased stress to the lower leg due to intrinsic risk factors, implementation of a strength and flexibility program, correction of training errors, and a gradual pain-free return to sport-specific activity. Nutritional counseling or hormonal therapy may also be necessary to ensure adequate structural support of the lower leg.

Treatment options for recalcitrant cases of shin splints may include prolonged immobilization with pain-free modified training, surgery to promote bone union, or fasciotomy.

Joshua C. Dubin, DC, CSCS, CCSP, is the owner of Dubin Chiropractic in Quincy, MA, and a member of the Team USA Triathlon/Duathlon International Triathlon Union medical staff since 1996. Rachel Appel Dubin, PT, DPT, is a staff physical therapist at Milton Hospital in Milton, MA. Gregory H. Doerr, DC, CCSP, is the owner of Bergen Chiropractic and Sports Rehabilitation Center in Cliffside Park, NJ.

References

1. Andrew JR, Harrelson GL, Wilk KE. *Physical rehabilitation of the injured athlete*, 3rd ed. Philadelphia: W. B. Saunders, 2004.
2. Reid DC. *Sports injury assessment and rehabilitation*. New York: Churchill Livingston, 1992.
3. Edwards PH Jr, Wright ML, Hartman JF. A practical approach for the differential diagnosis of chronic leg pain in the athlete. Am J Sports Med 2005;33(8):1241-1249.
4. Pellecchia GL, Hamel H, Behnke P. Treatment of infrapatellar tendonitis: a combination of modalities and transverse friction massage versus iontophoresis. J Sports Rehabil 1994;3(2):35-145.
5. Jensen J. Stress fracture in the world class athlete: a case study. Med Sci Sports Exerc 1998;30(6):783-787.
6. Chleboun GS, Busic AB, Graham KK, Stuckey HA. Fascicle length change of the human tibialis anterior and vastus lateralis during walking. J Orthop Sports Phys Ther 2007;37(7):372-379.
7. Hyde T. *Conservative management of sports injury*. Baltimore: Williams & Wilkins, 1997;477-482.
8. Gum SL, Reddy GK, Stehno-Bittel L, Enwemeka CS. Combined ultrasound, electrical muscle stimulation, and laser promote collagen synthesis with moderate changes in tendon biomechanics. Am J Phys Med Rehabil 1997;76(4):288-296.
9. Young B, Walker M, Strunce J, Boyles R. A combined treatment approach emphasizing impairment-based manual physical therapy for plantar heel pain: a case series. J Orthop Sports Phys Ther 2004;34(11):725-733.
10. Walker JM. Deep transverse frictions in ligament healing. J Orthop Sports Phys Ther 1984;6(2):89-94.
11. Brosseau L, Casimiro, Milne S, et al. Deep transverse friction massage for healing tendonitis. Cochrane Database Syst Rev 2002;(4):CD003528.
12. Kvist M, Jarvinen M. Clinical histochemical and biomechanical features in repair of

muscle and tendon injuries. Int J Sports Med 1982;(3 Suppl 1):12-14.
13. Roniger LR. Massage, strengthening reduce knee OA pain disability. Biomechanics 2007;14(2):17-18.
14. Dyck D, Boyajian-O'Neill LA. Plantar fasciitis. Clin J Sports Med 2004;14(5):305-309.
15. Leadbetter WB. Cell matrix response in tendon injury. Clin Sports Med 1992; 11(3):533-578.
16. Roniger LR. Research focus on lower limb pain brings relief. Biomechanics 2008;15(1):21-27.
17. Wall J, Feller JF. Imaging of stress fractures in runners. Clin Sports Med 2006; 25(4):781-802.
18. Kortebein PM, Kaufman KR, Basford JR, Stuart MJ. Medial tibial stress syndrome. Med Sci Sports Exerc 2000;32(3 Suppl):S27-S33.
19. Butler R, Davis I, Hamill J. Interaction of joint type and footwear on running mechanics. Am J Sports Med 2006;34(12):1998-2005.
20.Yates B, White S. The incidence and risk factors in the development of medial tibial stress syndrome among naval recruits. Am J Sports Med 2004;32(3):772-780.
21. Michaud TC. *Foot orthosis and other forms of conservative foot care.* Sydney, Aust.: Williams & Wilkins, 1997.
22. Donatelli RA. *The biomechanics of the foot and ankle.* 2nd ed. Philadelphia: F.A. Davis, 1996.
23. Fredericson M, Wun C. Differential diagnosis of leg pain in the athlete. J Am Podiatr Med Assoc 2003;93(4):321-324.
24. Filipou D, Kalliakmanis A, Triga A, et al. Sports related plantar fasciitis. Current diagnostic and therapeutic advances. Folia Med (Plovdiv) 2004;46(3):56-60.
25. Sobel E, Levitz S, Caselli M. Orthoses in the treatment of rearfoot problems. J Am Podiatr Med Assoc 1999; 89(5):220-233.
26. Landorf K, Keenan A, Herbert R. Effectiveness of different types of foot orthoses for the treatment of plantar fasciitis. J Am Podiatr Med Assoc 2004;94(6):542-549.
27. Kogler G, Veer F, Solomonidis S, Paul J. The influence of medial and lateral placement of orthotic wedges on loading of the plantar aponeurosis: an in vitro study. J Bone Joint Surg 1999; 81-A(10):1403-1413.
28. Landorf K, Radford J, Keenan A, Redmond A. Effectiveness of low-dye taping for the short term management of plantar fasciitis. J Am Podiatr Med Assoc 2005;95(6): 525-530.
29. Radford J, Burns J, Buchbinder R, et al. The effect of low-dye taping on the kinematic, kinetic, and electromyographic variables. J Orthop Sports Phys Ther 2006;36(4):232-241.
30. Shaffer RA, Rauh MJ, Brodine SK, et al. Predictors of stress fracture susceptibility in young female recruits. Am J Sports Med 2006;34(1):108-115.
31. Roxas M. Plantar fasciitis: diagnosis and therapeutic considerations. Altern Med Rev 2005;10(2):83-93.
32. Didiovanni B, Nawoczenski D, Lintal M, et al. Tissue-specific plantar fascia-stretching exercise enhances outcomes in patients with chronic heel pain: a prospective randomized study. J Bone Joint Surg 2003;85-A(7):1270-1277.
33. Mahieu N, McNair P, DeMuynck M, et al. Effect of static and ballistic stretching on the muscle-tendon tissue properties. Med Sci Sports Exerc 2007;39(3):494-501.
34. Spitz D, Newberg A. Imaging of stress fractures in the athlete. Radiol Clin North Am 2002;40(2):313-331.
35. Wilder RP, Sethi S. Overuse injuries: tendinopathies, stress fractures, compartment syndrome, and shin splints. Clin Sports Med 2004;23(1):55-81.
36. Larson CM, Traina SM, Fischer DA, Arendt EA. Recurrent complete proximal tibial stress fracture in a basketball player. Am J Sports Med 2005;33(12):1914-1917.
37. Yates B, Allen MJ, Barnes MR. Outcome of surgical treatment of medial tibial stress syndrome. J Bone Joint Surg 2003;85-A(10):1974-1980.
38. Norkin CC, Levangie PK. *Joint structure and function: a comprehensive analysis*, 2nd ed. Philadelphia: F.A. Davis, 1992.
39. Smurawa T. Overuse injuries curb triathlon preparation efforts. Biomechanics 2006;13(5):49-61.
40. Martin DE, Coe PN. *Better training for distance running*, 2nd ed. Champaign, IL: Human Kinetics, 1997.
41. Higdon H. Hal Higdon's Marathon Training Guide. www.halhigdon.com/ marathon/Mar00novice.htm, accessed 3/14/08.
42. Armstrong RB, Ogilvie RW, Schwane JA. Eccentric exercise-induced injury to rat skeletal muscle. J Appl Physiol 1983;54(1): 80-93.
43. Messier SP, Edwards DG, Martin DF, et al. Etiology of iliotibial band friction syndrome in distance runners. Med Sci Sports Exerc 1995;27(7):951-960.
44. Tommasini SM, Nasser P, Schaffler MB, Jepsen KJ. Relationship between bone morphology and bone quality in male tibias: implications for stress fracture risk. J Bone Miner Res 2005;20(8):1372-1380.
45. Inman VT. Human locomotion. Can Med Assoc J 1996; 94(2):1047-1054.
46. Woodley BL, Newsham-West RJ, Baxter GD. Chronic tendinopathy: effectiveness of eccentric exercise. Br J Sports Med2007; 41(4):188-199.
47. Banks AS, Downey MS, Martin De, Miller SJ. *McGlamrey's comprehensive textbook of foot and ankle surgery*, 3rd ed. Baltimore: Williams & Wilkins, 2001.
48. Friden J, Sfakianos PN, Hargens AR. Muscle soreness and intramuscular fluid pressure: comparison between eccentric and concentric load. J Appl Physiol 1986; 61(6):2175-2179.
49. Allen RH, Gross MT. Toe flexors strength and passive extension range of motion of the first metatarsophalangeal joint in individuals with plantar fasciitis. J Orthop Sports Phys Ther 2003;33(8):468-478.
50. Comfort P, Kasim P. Optimizing squat technique. J Strength Cond Res 2007; 29(6):10-13.
51. Witvrouw E, Mahieu N, Roosen P, McNair P. The role of stretching in tendon injuries. Br J Sports Med 2007;41(4):224-226.
52. Witvrouw E, Mahieu N, Danneels L, McNair P. Stretching and injury prevention: an obscure relationship. Sports Med 2004;34(7): 443-449.
53. Herring K. A plyometic training model used to augment rehabilitation from tibial fasciitis. Curr Sports Med Rep 2006;5(3): 147-154.
54. Noakes T. *The lore of running*, 4th ed. Champaign, IL: Human Kinetics, 2003;803-816.
55. Richie D, DeVries H, Endo C. Shin muscle activity and sports surfaces. J Am Podiatr Med Assoc 1993;83(4):181-190.
56.Chmielewski TL, Myer GD, Kauffman D, Tillman SM. Plyometric exercise in the rehabilitation of athletes: physiological responses and clinical application. J Orthop Sports Phys Ther 2006;36(5):308-319.

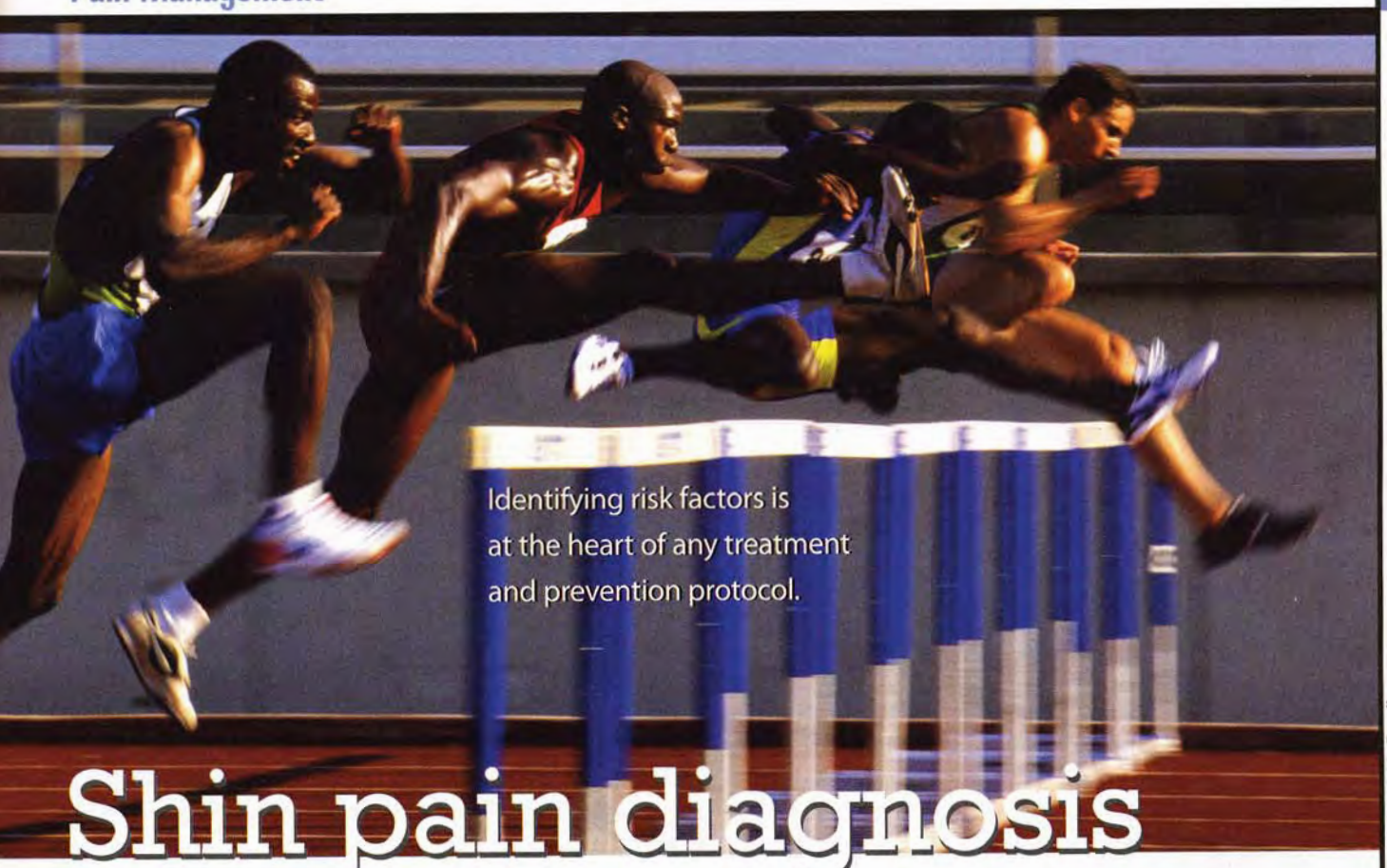

Identifying risk factors is at the heart of any treatment and prevention protocol.

Photo by Mike Powell

Shin pain diagnosis requires multipronged clinical approach

Athletes who participate in sports that require both prolonged and quick bursts of running and/or jumping are familiar with shin splints, one of the most common exercise-induced lower extremity injuries.[1] Symptoms may include pain over the anterolateral or the distal two-thirds of the posteromedial aspect of the shin.[2-6] These symptoms are usually present with activity and are alleviated with rest.[7]

by Joshua Dubin, DC, Rachel Appel Dubin, DPT, and Gregory Doerr, DC

Risk factors that may predispose an individual to develop shin splints include training errors, foot shape and biomechanics, poor preseason conditioning, and high body mass index.

If the athlete continues to train through the pain and a proper treatment program is not initiated, the symptoms and severity of the injury may progress. Activities that involve repetitive ground reaction forces associated with running and jumping may include long-distance running, track and field, soccer, basketball, and volleyball. Military recruits in basic training may also develop this problem.[7-11]

During running each foot strikes the ground 50 to 70 times per minute or a total of 800 times per mile, with the force of two to four times body weight.[1,12] The muscles, tendons, and bones that support the lower extremity can usually adapt to increased workloads associated with running if the training program progresses properly. However, various risk factors may predispose an individual to the development of shin splints by increasing ground reaction forces that act on the lower extremity or on a compromised musculoskeletal structure. These factors include training errors, foot shape and biomechanics, poor preseason conditioning, high body mass index, poor nutritional habits, and age-related degenerative changes.[1,13-16]

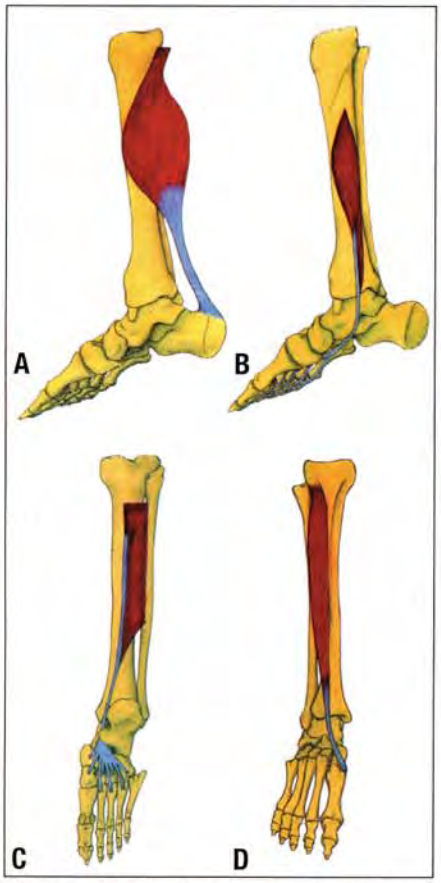

Figure 1. Muscles that attach to the tibia's posterior surface include the soleus (A), flexor digitorum longus (B), and tibialis posterior (C). The tibialis anterior (D) attaches to the anterolateral surface of the tibia. (All illustrations in this article by Audrey Mahoney)

The initial definition of shin splints was any type of pain from the hip to the ankle.[14] Though broad, it seemed appropriate in the mid-1900s because treatment algorithms for lower extremity injuries were in their rudimentary form and were relatively ineffective. Over the last four decades, medical research has led to advancements in understanding the causes, treatment, and prevention of sports injuries. Although the exact pathophysiology of shin splints remains unknown, several possible etiologies have been considered.[1,17,18]

An understanding of the kinesiology, physiology, and anatomy of the lower leg, and of risk factors associated with shin splints, along with a detailed history and physical examination may aid the practitioner in developing a proper treatment and prevention protocol.[3,19,20] Most cases of shin splints can be effectively treated with conservative care.[1,21]

Anatomy of the lower leg

Long bones such as the tibia have a rigid outer layer of compact bone. The external surface of the compact bone consists of several concentric rings of cortical bone, which is surrounded by periosteum, a thin layer of dense fibrous connective tissue that is richly innervated by nerves and blood vessels. Anchored to the cortical bone by bundles of connective tissue, or "Sharpey fibers," the periosteum has several functions. It protects the underlying bone and participates in its repair and remodeling process and is the site of attachment of adjacent muscles. Muscles consist of bundles of individual muscle fibers (fasciculi); each fiber is surrounded by endomysium, a thin, delicate layer of connective tissue. The fibrocartilage strands of the periosteum intertwine with the endomysium of abutting musculature to create an extensive origin of attachment. At this attachment, the underlying cortical bone is rough or thickened due to bone remodeling because of muscle traction.[22,23]

The tibia has three potential sites for muscle attachment: a posterior surface, and an anterolateral and a medial surface that are separated by the anterior tibial crest. The soleus, flexor digitorum longus, and tibialis posterior musculature connect to the posterior surface of the tibia. The tibialis anterior musculature attaches to the anterolateral surface of the tibia (Figures 1A-D). These muscles are contained within the superficial posterior, the deep posterior, or the anterior compartment of the leg (Figure 2).

The superficial posterior compartment houses the soleus musculature and is bounded posteriorly by the crural fascia and anteriorly by the transverse fascia. The deep posterior compartment contains the flexor digitorum longus and the tibialis posterior musculature. The tibialis anterior muscle is contained within the anterior compartment of the leg.[3,6,24,25] These muscles surrounding the shin aid in coordinating movements of the foot and ankle and in reducing ground reaction forces associated with running and jumping.

Lower leg biomechanics during ambulation

Gait consists of the stance phase and the swing phase for each leg. During the stance

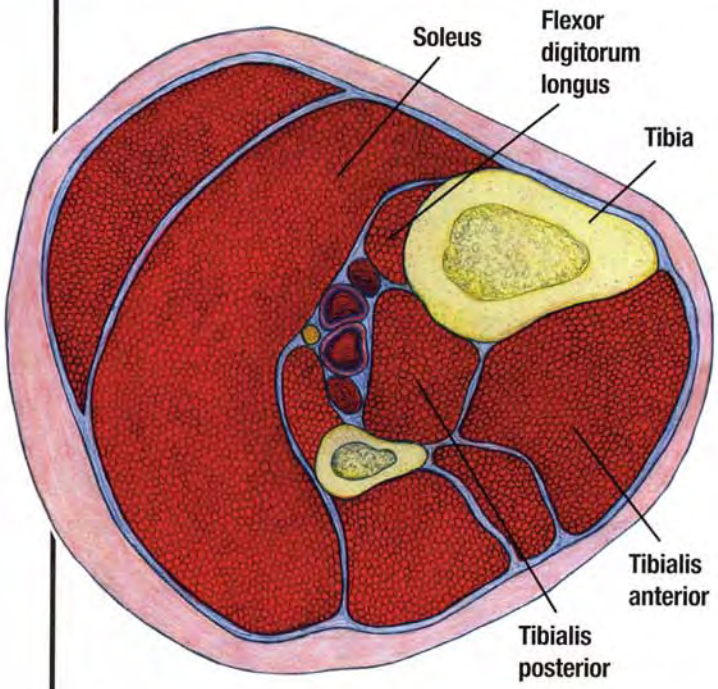

Figure 2. Cross section of the lower leg shows the position of the tibia and surrounding musculature.

phase, the foot contacts and adapts to the ground surface. The swing phase begins when the stance leg lifts off of the ground. Most sport-related injuries can be attributed to the repetitive ground reaction forces occurring during the stance phase.[26]

The stance phase of gait comprises five subphases: initial contact, loading response, early midstance, late midstance, and terminal stance. During initial contact, the foot of the swing leg meets the ground. Loading response begins shortly after initial contact as the foot begins to adapt to the terrain. Early midstance commences as the contralateral swing leg is midline with the body and distributes the body weight over the stance leg. Late midstance starts when the foot of the stance leg changes from a mobile adaptor to a more rigid lever as the foot prepares for toe-off. Terminal stance begins shortly after heel lift and ends with toe-off.[27-29]

Sequenced movements of the articulations of the rearfoot during the stance phases are pivotal in determining the function of the foot and ankle. The rearfoot is composed of the talocrural and the subtalar joints. The talocrural joint (ankle mortise) consists of the articulation of the distal aspect of the tibia and the fibula with the trochlea of the talus.

The subtalar joint (STJ) consists of the articulation of the undersurface of the talus with the calcaneus (heel bone).[24,27,30]

Throughout loading response and into early midstance, the foot goes through pronation, a series of transformations that allow the lower extremity to be more efficient in absorbing ground reaction forces. Pronation of the foot and ankle consists of the following movements: the STJ pronates, the heel bone turns outward (everts), and the talus drops downward distally and adducts toward the midline as the medial longitudinal arch (instep arch) lowers towards the ground; ground reactive dorsiflexion occurs at the talocrural joint, the tibia approximates to the toes, and the forefoot turns outward, or abducts (Figure 3). Normal range of pronation is 4° of heel eversion and 20° of ground reactive dorsiflexion. Pronation of the foot and ankle should terminate before late midstance as the foot prepares for toe-off.[24,27,28]

Shortly after the foot strikes the ground, the muscles attached to the anterior and posterior aspects of the tibia contract eccentrically; the muscle fibers elongate as that tension attempts to decelerate. The soleus, tibialis posterior, and flexor digitorum muscles have points of origin on the posterior aspect of the tibia and contract eccentrically during loading response and into midstance to decelerate pronation. Shortly after initial ground contact, the tibialis anterior contracts eccentrically to decelerate foot slap, when the forefoot descends towards the ground.[24,31]

Under normal circumstances, the musculoskeletal support structures of the lower extremity can adapt to these repetitive eccentric loads associated with running. However, training errors, structural abnormalities, and other risk factors may predispose a runner to excessive eccentric loads placed on the lower leg's musculature. This

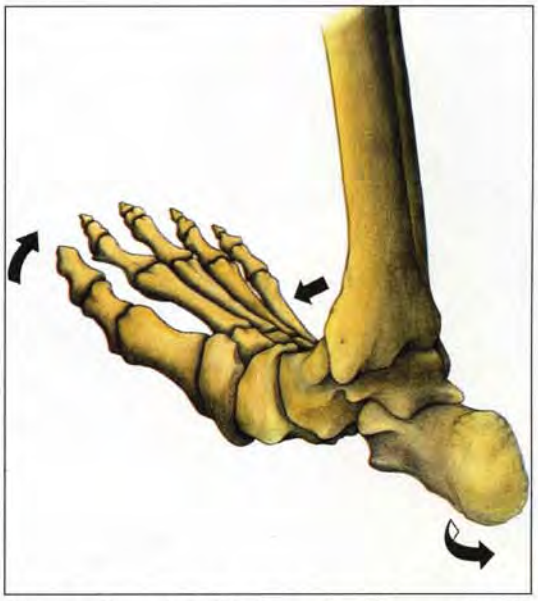

Figure 3. Pronation of the foot and ankle occurs after the foot contacts the ground. The ankle pronates, the talocrural joint dorsiflexes, the subtalar joint everts, and the forefoot abducts.

can result in anterolateral or posteromedial shin splints. Although the exact pathophysiology of shin splints has not been determined, research has come up with several hypothetical causes.

Possible etiologies

Various causes have been ascribed to shin pain.

Traction periostitis/periostalgia. In 1964 the American Medical Association defined shin splints as "pain and discomfort in the leg from repetitive activity on hard surfaces, or due to forcible excessive use of the foot flexors."[1] Current research supports the hypotheses that posteromedial shin pain in running athletes may be caused by excessive eccentric contractions of the superficial and deep posterior compartment muscles that originate on the tibia. Training errors that do not allow for proper adaptation of the musculoskeletal support structures of the lower leg to increased workloads may lead to inflammation or degenerative changes to the surrounding fascia (fasciitis) or to the periosteum (periostitis/periostalgia).[2,6,26]

Posteromedial shin pain due to traction periostitis has been given several different names. Posterior tibial syndrome (PTS) was first used in 1978 to describe posteromedial shin pain due to a traction periostitis involving the origin of the tibialis posterior musculature.[1,32] Medial tibial stress syndrome (MTSS) was introduced in 1982 to encompass any of the origins of the deep flexor muscules of the leg that attach to the tibia as possible causes of traction periostitis.[1,32]

In 1985, Michael and Holder[1,32] coined the term soleus syndrome. Using bone scintigraphy and biopsies, they diagnosed complaints of posteromedial leg pain, and found increased bone remodeling and periostitis at the origin of the soleus muscle on the medial aspect of the tibia. However, other studies involving biopsies of patients diagnosed with posteromedial shin splints did not confirm inflammation of the periosteum.[17] Based on those studies, it has been hypothesized that shin pain may instead be caused by a degenerative periostalgia. MTSS is currently the most common term used to describe posteromedial shin pain thought to be caused by periostitis or periostalgia.[1,19]

Anterolateral shin pain has been linked to repetitive eccentric contractions of the tibialis anterior muscle. Downhill running accentuates a more pronounced foot slap, which can predispose the tibialis anterior to fatigue. This may result in anterolateral shin pain or anterior tibial stress syndrome (ATSS) due to a similar mechanism of injury as MTSS.[14]

Bone stress reaction. Bone remodeling of the tibia in response to increased workloads commences approximately five days after stimulation.[2] Two types of cells are active in bone remodeling: osteoblasts and osteoclasts. Osteoclast cells react to this increased stress by breaking down bone. Bone resorption is followed by osteoblast secretion of osteoid, or uncalcified bone. Osteoid calcifies into new bone after interacting with calcium and phosphate ions. These adaptations should result in a stronger, more rigid skeletal support structure, although the process may take 90 days.[14]

Overtraining may lead to a higher ratio of bone resorption by osteoclast cells to the production of new bone by osteoblast cells. A compromised skeletal support structure, which is susceptible to a bone stress reaction, may result.[1,10,11] Bone stress reactions may include microfractures, or, in more advanced stages, a stress fracture. Stress fractures in athletes occur most commonly in the tibia at about four to five weeks after beginning a new exercise regimen.[12,19,33,34]

Exercise-induced compartment syndrome. Increased intracompartmental pressures due to exercise are most commonly found in the anterior and deep posterior compartments of the leg.[4] Repetitive eccentric contractions of the calf muscles may lead to the release of protein ions due to microtrauma. This results in increased intracompartmental swelling, decreased blood flow, and ischemia; this eventually can lead to muscle dysfunction and shin pain.[4,35] The treatment of posteromedial or anterolateral shin splints in minor injuries is similar whether the cause is a traction periostitis/periostalgia, bone stress reaction, or ECS.[1,19] The initial history and physical examination should focus on discovering possible risk factors. Treatment and prevention should then include steps to minimize these risk factors.

Risk factors

Risk factors associated with shin splints can be separated into intrinsic and extrinsic categories (Table 1).[6,36] Intrinsic risk factors may include structural abnormalities such as pes planus (flat foot); forefoot varus (inversion in relation to the rearfoot, Figure 4A); rearfoot varus (inverted position of the back of the heel, Figure 4B); and ankle equinus (limited dorsiflexion of the ankle joint most likely caused by diminished flexibility of the posterior calf musculature). These abnormalities may lead to prolonged or excessive pronation of the STJ and predispose an individual to shin splints.[1,2,8,24,32]

Conversely, a pes cavus structure (high arch that is usually restricted in pronation) is limited in its ability to absorb ground reaction forces. This leads to an increased workload on the tibia, which can predispose a person to a bone stress reaction.[15,24]

Most risk factors are correctable or can be minimized.

Severity of symptoms and level of injury are generally scored on a four-grade system:

- Grade 1. Pain is present at the end of the workout but is minimal;
- Grade 2. Pain is present during the workout but does not affect performance;
- Grade 3. Pain during the workout affects performance but dissipates when activity ends;
- Grade 4. Pain does not allow participation in sport and is now present during activities of daily living.[1] Usually the athlete will seek treatment when pain hinders performance.

Diagnosing shin splints

The history should include the following: initial onset of injury; current symptoms; progression of the frequency, intensity, and duration of the weekly training runs; training surface; whether training runs incorporate hills; age and type of running shoes; recent weight fluctuations; past history of stress fractures; lower extremity strength training and flexibility program; and training goals.[16,35]

Palpation may reveal diffuse tenderness over the distal two-thirds of the posteromedial aspect (MTSS) or the anterolateral aspect of the shin (ATSS).[16,19,32] However, palpation that reveals focal tenderness localized to bone and edema, erythema, and an inability to run due to severe pain at that localized sight, may

be a red flag for a bone stress reaction.[14,17,19] Vibratory irritation with a tuning fork or ultrasound may exacerbate symptoms related to more severe cases of bone stress reactions; these findings, however, are not typically reliable.

Provocative testing may be needed. These tests are meant to increase eccentric strain on the posterior calf muscles that attach to the tibia; thereby leading to or exacerbating symptoms related to MTSS. These tests may include one-legged hops on an unstable surface, such as a trampoline or a foam cushion; passive dorsiflexion of the foot by the practitioner with the patient prone and the knee flexed; or the patient applying a ground reaction force to the talocrural joint by assuming a lunge position with the affected limb forward, and then pushing upwards on an undersurface of a railing or counter surface with the ipsilateral hand.[6,32]

Visual observation of the medial longitudinal arch and the instep may reveal a pes planus or pes cavus foot structure. Using a goniometer, a more detailed analysis of foot structure and compensatory movements can be obtained in the nonweight-bearing and weight-bearing positions.[24,27,28]

If the patient is not improving with conservative care or the clinical diagnosis is unclear, radiographs or advanced imaging techniques can prove helpful in differentiating between shin pain due to MTSS/ATSS, a bone stress reaction, or other pathology.

Advanced imaging techniques

Radiographs are routinely taken of the leg in patients experiencing shin pain. This baseline study may reveal a periosteal reaction, callus formation, or a radiolucent line, which are common findings of a bone stress reaction or frank stress fracture. Other pathological conditions, such as an osteoid osteoma, osteosarcoma, or Ewing's sarcoma, may also be ruled out with an x-ray.

However, bone stress reactions are usually not visualized on x-ray until the second to sixth week postinjury or initial complaints of symptoms.[1,21,35,37] Sensitivity of early fracture detection by radiography can be as low as 15%, and follow-up x-rays may demonstrate diagnostic findings in only 50% of cases.[16]

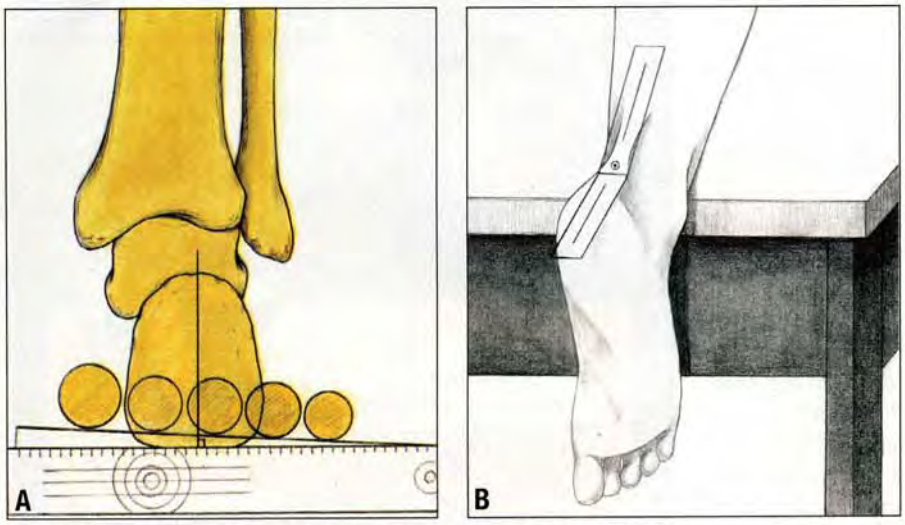

Figure 4. Intrinsic risk factors associated with shin splints include forefoot varus (A) and rearfoot varus (B), both of which can be measured with a goniometer.

More advanced studies, such as an MRI or a bone scan, may be needed for further evaluation. These studies are more sensitive in detecting bone pathology in the earlier stage of injury than radiographs. They can aid in developing a treatment plan for a gradual return to sport-specific training or one that may require a longer period of modified rest, immobilization, or corrective surgery for more advanced cases of bone-stress reactions.[1,10,38]

MRI is highly sensitive to edema in musculoskeletal structures. Two different types of sequences may be used: a T1-weighted sequence that depicts anatomy and more advanced signal abnormalities in the cortical bone; and either a short tau inversion recovery (STIR) or a T2-weighted frequency-selective fat suppression sequence, which is more sensitive to edema in the muscle, periosteum, or bone marrow.[12,21,38]

Frederickson et al[35] developed a graded classification of MRI findings and the severity of bone stress reactions. Grade 1 injuries demonstrate mild periosteal edema on the T2-weighted images only. Grade 2 injuries show more severe periosteal edema with bone marrow edema than that detected on T2-weighted images only. Grade 3 injuries depict moderate to severe edema of both the periosteum and bone marrow on T2-weighted and also on the T1-weighted images. Grade 4 injuries show a low signal fracture line with changes of severe marrow edema on both T1-weighted and T2-weighted sequences. When pain was present during training and normal ambulation, there was an 81% incidence of a grade 3 or 4 injury as depicted by MRI.[16,35]

A bone scan is highly sensitive in detecting osteoblast activity that occurs in bone remodeling. Usually a triple-phase bone scan, which involves a preinjection of the technetium-99m methylene diphosphonate isotope, is conducted. In the first phase—blood flow—images are taken over the symptomatic area for 60 seconds. In the second phase—blood pool—images are taken for five minutes immediately after the blood flow phase. In the third phase—delayed skeletal—images are taken two to six hours after the initial injection. The delayed images allow the isotope to clear from the adjacent soft tissue; under normal circumstances, approximately 50% of the isotope is absorbed into the skeletal system. The amount of radiotracer absorption depends on the rate of bone remodeling and osteoblastic activity.

Less severe bone stress injuries are depicted as ill-defined foci of increased isotope absorption and are located predominantly in the cortical region of bone. More severe injuries involve a higher rate of bone remodeling, which results in increased isotope resorption and wide fusiform lesions that extend from the cortical bone into the medullary bone.[4,17,39] Acute stress fractures would be positive for increased isotope activity on all three phases. Soft tissue injuries would indicate increased uptake in the initial two phases but not in the delayed skeletal phase. MTSS would show linear foci of increased isotope uptake along the posterior border of the tibia in the delayed skeletal phase only.[40]

TABLE: RISK FACTORS ASSOCIATED WITH SHIN SPLINTS

Intrinsic	Extrinsic
Lower limb structural abnormalities: pes planus, rearfoot varus, forefoot varus, ankle equinous, and pes cavus	Training errors: inappropriate progression of intensity, frequency, or duration of training program
Poor conditioning, overweight (body mass index > 30 kg/m2); insufficient muscle endurance and strength; limited flexibility	Unsuitable footwear
Female triad—osteoporosis, amenorrhea, and an eating disorder	Poor training surface that is either hard and unyielding or uneven
Age-related changes that are especially noticeable after 40	Hill training before a proper base is established
History of previous stress fractures	Type of sport

Source: Refs.:1,2,4,10, 11,14-16,19,22,33-36,41

An MRI or bone scan study can be a valuable tool for early detection and differentiation between shin pain due to MTSS/ATSS, a bone stress reaction, or other pathology. These advanced imaging studies may prove useful in avoiding complications due to undetected bone stress reactions or other pathologies. However, advanced imaging findings can be vague. Previous imaging studies have indicated false-positive findings present in asymptomatic patients; false-negative findings also have been noted.[3,12,16,39] Therefore, the practitioner should correlate MRI and bone scan findings with clinical examination findings.

The hallmark test for ECS is intracompartmental pressure measurement with a slit catheter. These measurements are taken before exercise (see "Shin pain treatments get active patients back on track," April, page 31), and then at one and five minutes postexercise. Measurements consistent with an ECS diagnosis are a preexercise pressure of ≥ 15 mm Hg; one-minute postexercise pressure of ≥ 30 mm Hg; or five-minute postexercise pressure ≥ 20 mm Hg.[19]

In anterior compartment syndrome, muscle testing may reveal weak dorsiflexion of the foot, and paresthesthesia may be present on the dorsum of the foot. In deep posterior compartment syndrome, muscle testing may reveal weakness in plantar flexion and inversion, and paresthesias may be observed on the plantar aspect of the foot.[1]

Joshua C. Dubin, DC, CSCS, CCSP, is the owner of Dubin Chiropractic in Quincy, MA, and a member of the Team USA Triathlon/Duathlon International Triathlon Union medical staff since 1996. Rachel Appel Dubin, PT, DPT, is a staff physical therapist at Milton Hospital in MA. Gregory H. Doerr DC, CCSP, is the owner of Bergen Chiropractic and Sports Rehabilitation Center in Cliffside Park, NJ.

This is part I of a two-part article. Next month, part II will look at prevention and treatment options for shin pain.

References

1. Reid DC. Sports injury assessment and rehabilitation. New York: Churchill Livingston, 1992.
2. Yates B, White S. The incidence and risk factors in the development of medial tibial stress syndrome among naval recruits. Am J Sports Med 2004;32(3):772-780.
3. Hislop M, Tierney P. Anatomical variations within the deep posterior compartment of the leg and important clinical consequences. J Sci Med Sport 2004;7(3):392-399.
4. Wilder RP, Sethi S. Overuse injuries: tendinopathies, stress fractures, compartment syndrome, and shin splints. Clin Sports Med 2004;23:55-81.
5. Magnusson HI, Westlin NE, Nyquist F, et al. Abnormally decreased regional bone density in athletes with medial tibial stress syndrome. Am J Sports Med 2001;29(6):712.
6. Herring K. A plyometic training model used to augment rehabilitation from tibial fasciitis. Curr Sports Med Rep 2006; 5(3):147-54.
7. Batt ME, Ugalde V, Anderson MW, Shelton DK. A prospective controlled study of diagnostic imaging for acute shin splints. Med Sci Sports Exerc 1998;30(11):1564-1571.
8. Thacker SB, Gilchrist J, Stroup DF, Kimsey CD. The prevention of shin splints in sports: a systematic review of literature. Med Sci Sports Exerc 2002;34(1):32-40.
9. Korpelainen R, Orava S, Karpakka J, et al. Risk factors for recurrent stress fractures in athletes. Am J Sports Med 2001;29(3): 304-310.
10. Jensen J. Stress fracture in the world class athlete: a case study. Med Sci Sports Exerc 1998;30(6):783-787.
11. Tommasini SM, Nasser P, Schaffler MB, Jepsen KJ. Relationship between bone morphology and bone quality in male tibias: implications for stress fracture risk. J Bone Miner Res 2005;20(8):1372-1380.
12. Wall J, Feller JF. Imaging of stress fractures in runners. Clin Sports Med 2006; 25(4):781-802.
13. Sommer HM, Vallentyne SW. Effect of foot posture on the incidence of medial tibial stress syndrome. Med Sci Sports Exerc 1995; 27(6):800-804.
14. Noakes T. The lore of running, 4th ed. Champaign, IL: Human Kinetics, 2003: 803-816.
15. Shaffer RA, Rauh MJ, Brodine SK, et al. Predictors of stress fracture susceptibility in young female recruits. Am J Sports Med 2006;34(1):108-115.
16. Spitz D, Newberg A. Imaging of stress fractures in the athlete. Radiol Clin North Am 2002; 40(2):313-331.
17. Bhatt R, Lauder I, Finlay DB, et al. Correlation of bone scintigraphy and histological findings in medial tibial syndrome. Br J Sports Med 2000;34(1):49-53.
18. Magnusson HI, Ahlborg HG, Karlsson C, et al. Low regional tibial bone density in athletes with medial tibial stress syndrome normalizes after recovery from symptoms. Am J Sports Med 2003;31(4):596-600.
19. Edwards PH Jr, Wright ML, Hartman JF. A practical approach for the differential diagnosis of chronic leg pain in the athlete. Am J Sports Med 2005;33(8):1241-1249.
20. Bennell K, Crossley K, Jayarajan J, et al. Ground reaction forces and bone parameters in females with tibial stress fracture. Med Sci Sports Exerc 2004; 36(3): 397-404.
21. Aoki Y, Yasuda K, Tohyama H, et al. Magnetic resonance imaging in stress fractures and shin splints. Clin Orthop Relat

Res 2004;421:260-267.
22. Weineck J. Functional anatomy in sports, 2nd ed. St. Louis: Mosby-Year Book, 1990.
23. Wheater PR, Burkitt HG, Daniels VG. Functional histology. New York: Churchill Livingstone, 1987.
24. Banks AS, Downey MS, Martin DE, Miller SJ. McGlamrey's comprehensive textbook of foot and ankle surgery, 3rd ed. Baltimore: Williams & Wilkins, 2001.
25. Clemente CD. Anatomy: A regional atlas of the human body, 3rd ed. Baltimore: Urban & Schwarzenberg, 1987.
26. Richie D, DeVries H, Endo C. Shin muscle activity and sports surfaces. J Am Podiatr Med Assoc 1993;83(4):181-190.
27. Michaud TC. Foot orthosis and other forms of conservative foot care. Sydney, Aust.: Williams & Wilkins, 1997.
28. Donatelli RA. The biomechanics of the foot and ankle, 2nd ed. Philadelphia: F.A. Davis, 1996.
29. Norkin CC, Levangie PK. Joint structure and function: a comprehensive analysis, 2nd ed. Philadelphia: F.A. Davis, 1992.
30. Inman VT. Human locomotion. Can Med Assoc J 1996;94(2):1047-1054.
31. Chleboun GS, Busic AB, Graham KK, Stuckey HA. Fascicle length change of the human tibialis anterior and vastus lateralis during walking. J Orthop Sports Phys Ther 2007;37(7):372-379.
32. Kortebein PM, Kaufman KR, Basford JR, Stuart MJ. Medial tibial stress syndrome. Med Sci Sports Exerc 2000;32(3 Suppl):S27-S33.
33. Larson CM, Traina SM, Fischer DA, Arendt EA. Recurrent complete proximal tibial stress fracture in a basketball player. Am J Sports Med 2005;33(12):1914-1917.
34. Pozderac RV. Longitudinal tibial fatigue fracture: an uncommon stress fracture with characteristic features. Clin Nucl Med 2002;27(7):475-478.
35. Fredericson M, Wun C. Differential diagnosis of leg pain in the athlete. J Am Podiatr Med Assoc 2003;93(4):321-324.
36. Reinking MF, Austin TM, Hayes AM. Exercise-related leg pain in collegiate cross-country athletes: extrinsic and intrinsic risk factors. J Orthop Sports Phys Ther 2007; 37(11):670-678.
37. Ruohola JPS, Kiuru MJ, Pihlajamaki HK. Fatigue bone injuries causing anterior lower leg pain. Clin Orthop Relat Res 2006; 444:216-223.
38. Gaeta M, Minutoli F, Vinci S, et al. High-resolution CT grading of tibial stress reactions in distance runners. AJR Am J Roentgenol 2006;187(3):789-793.
39. Hod N, Ashkenazi I, Levi Y, et al. Characteristics of skeletal stress fractures in female military recruits of the Israeli Defense Forces on bone scintigraphy. Clin Nucl Med 2006; 31(12):742-749.
40. Love C, Din AS, Tomas MB, et al. Radionuclide bone imaging: an illustrative review. Radiographics 2003;23(2):341-358.
41. Taunton JE, Ryan MB, Clement DB, et al. A restrospective case-control analysis of 2002 running injuries. Br J Sports Med 2002;36(2):95-101.